

Original Article

Ultrasonographic evaluation at 6-month follow-up of plantar fasciitis after extracorporeal shock wave therapy

Dietrich S. Hammer · Frank Adam (✉) · Andreas Kreutz · Stefan Rupp · Dieter Kohn · Romain Seil

D. S. Hammer · F. Adam · A. Kreutz · S. Rupp · D. Kohn · R. Seil
Orthopaedic University Hospital , 66421 Homburg/Saar, Germany

✉ F. Adam
Phone: +49-6841-1624500
Fax: +49-6841-1624580
E-mail: frank.adam@uniklinik-saarland.de

Received: 17 February 2003

Abstract *Introduction* The aim of this study was to investigate the effect of extracorporeal shock wave therapy (ESWT) on the ultrasonographic appearance of chronically painful, proximal plantar fasciitis.

Materials and methods Twenty-two patients with a unilateral proximal plantar fasciitis were prospectively enrolled after unsuccessful conservative treatment lasting 6 months. The contralateral plantar fascia was used as the control. ESWT (3×3000 shock waves/session of 0.2 mJ/mm²) was performed at weekly intervals. The thickness of the plantar fascia was measured ultrasonographically about 2 cm distal of the medial calcaneal tuberosity. Pain estimation on a visual analogue scale (VAS) and the comfortable walking time were recorded. No local anaesthesia was applied. Follow-up was done at 6, 12 and 24 weeks.

Results Before ESWT, the plantar fasciitis side was ultrasonographically significantly thicker than the control side ($p<0.05$), whereas 6 months after ESWT, the thickness of the fascia was no longer significantly different. The decrease in thickness of the plantar fasciitis side was significant ($p<0.05$). Pain during activities of daily living decreased by 79% according to the VAS, and the

comfortable walking time increased, both significantly ($p<0.01$). In patients with little pain (VAS<30), the thickness of the plantar fasciitis side was significantly less ($p<0.01$) compared with patients who still suffered more pain (VAS>30).

Conclusion After ESWT, the thickness of the plantar fascia in patients with plantar fasciitis decreased, pain and walking time improved (all significantly).

Keywords Plantar fasciitis · Extracorporeal shock wave therapy · Ultrasonography

Introduction

Plantar fasciitis is a common clinical problem. Patients present with pain on the plantar side of the foot, often near the medial side of the calcaneal tuberosity. The exact aetiology is unknown. Association with obesity, middle age, pes planus, pes cavus or tight Achilles tendon has been described. A heel spur is not considered pathognomonic of the disorder, although it is often detected [8, 20, 21].

Apart from the clinical examination, ultrasonographic evaluation and magnetic resonance imaging (MRI) can provide further information to confirm the diagnosis of plantar fasciitis. MRI studies found a significantly increased plantar fascia thickness in patients with plantar fasciitis (mean 6.7 and 7.4 mm) compared with a healthy control group (mean 3.2 and 3.3 mm) [2, 31]. Ultrasonographic studies presented similar significant differences, with a mean thickness of the plantar fasciitis side ranging between 5.2 and 5.7 mm, and a mean thickness of an asymptomatic plantar fascia between 2.6 and 3.8 mm [5, 13, 34, 35].

The therapy of choice is conservative. It is effective in approximately 90% of patients [8]. Non-steroidal anti-inflammatory drugs, local steroid injections, heel cups, orthotics and/or shoe modifications, electrotherapy and physiotherapy with stretching exercises are used [7, 17, 30, 37]. In the remaining 10% of patients, surgical intervention is recommended [6, 28].

The use of extracorporeal shock wave therapy (ESWT) as a further non-surgical method in orthopaedics and traumatology began more than 10 years ago. Since then, ESWT has been used to treat various insertional tendopathies and delayed unions and non-unions of fractures [9, 10, 14, 15, 16, 22, 23, 24, 25, 26, 27, 29].

The aim of this study was to investigate the effect of ESWT on the ultrasonographic appearance of chronically painful, proximal plantar fasciitis.

Patients and methods

Between January 1999 and August 1999, 22 patients with an unilateral proximal plantar fasciitis were prospectively enrolled in a clinical study after unsuccessful conservative treatment lasting at least 6 months. The contralateral plantar fascia was used as the control.

Previously applied treatment consisted of non-steroidal anti-inflammatory drugs (NSAIDs), local steroid injections, heel cups or orthotics, and electrotherapy (iontophoresis with diclofenac). A heel spur was present in all patients on the symptomatic side. Exclusion criteria were neurological disorders, local infections, local tumours, coagulation disorders and pregnancy.

After enrollment, treatment of the unilateral plantar fasciitis consisted of three sessions of ESWT (3000 shock waves/session of 0.2 mJ/mm^2) at weekly intervals. No local anaesthesia was applied. The ESWT was performed with the Piezoson 300 (Richard Wolf, Knittlingen, Germany), a piezo-electric system with inline ultrasound detection (Fig. 1).

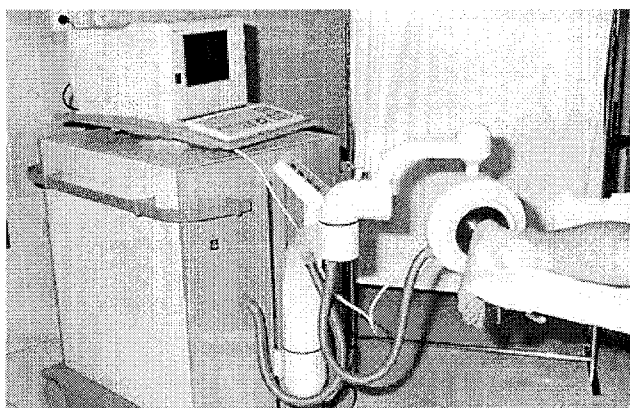


Fig. 1. Position of the patient for extracorporeal shock wave therapy (ESWT) at the medial aspect of the calcaneal tuberosity with the application tube in place

At the 12-week follow-up 2 patients were lost, and another 4 patients at the 24-week follow-up. At the time of enrollment, the group consisted of 5 men and 17 women, with an average age of 51.6 years (range 24–79 years). The duration of symptoms was 8.8 months (range 6–12 months), the length of the spur (symptomatic side) on a lateral X-ray measured 3.4 mm (range 1–11 mm). The body mass index averaged 30.2 kg/m^2 (range $22\text{--}36.5 \text{ kg/m}^2$), and the European shoe size was 40.4 (range 36–45).

A clinical investigation including ultrasonography was carried out before ESWT and at follow-up appointments (6, 12, 24 weeks after completion of ESWT). The thickness of the plantar fascia was measured about 2 cm distal of the medial calcaneal tuberosity (Fig. 2). Pain estimation on a

visual analogue scale (VAS) [12] ranging from no pain (0) to maximal pain (100) regarding different situations (rest, activities of daily living and one-leg stance) was assessed, and the comfortable walking time recorded. Statistical analysis was done with the non-parametrical Wilcoxon test for paired samples and the non-parametrical U-test (Mann-Whitney) for unpaired samples.

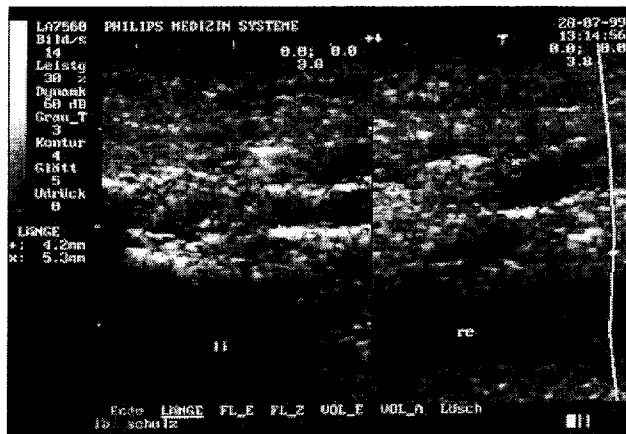


Fig. 2. Ultrasonographic longitudinal appearance (linear scanner) of the plantar fascia. Asymptomatic left side with 4.2 mm thickness (+) and symptomatic right side with 5.3 mm thickness (x)

Results

Before ESWT, the mean thickness of the plantar fascia was significantly ($p < 0.05$; U-test) greater on the symptomatic side (5.2 ± 1.5 mm) than on the asymptomatic (control) side (4.3 ± 1.1 mm). With the numbers available, we found no significant differences in the thickness of the plantar fascia between the symptomatic and the control side at the 6, 12 and 24 week follow-ups. Six months after ESWT, the decrease in thickness of the plantar fasciitis (5.2 ± 1.5 to 4.4 ± 1.0 mm) was significant ($p < 0.05$; Wilcoxon test). With the numbers available, we detected no significant change of thickness on the control side (Table 1).

[Table 1. will appear here. See end of document.]

Six months after ESWT, pain estimation by the patients on the VAS had improved significantly ($p < 0.01$; Wilcoxon test) in all test situations. At rest the pain declined by 82%. During activities of daily living and during single-leg stance, the pain decreased by 79%. The comfortable walking time increased significantly ($p < 0.01$; Wilcoxon test) 6 months after ESWT (Table 2).

[Table 2. will appear here. See end of document.]

Those patients with little pain (VAS<30; $n=13$) during everyday life 6 months after ESWT showed significantly ($p<0.01$; U-test) thinner plantar fascias on the symptomatic side compared with patients with more pain persisting ($n=3$) (4.1 ± 0.6 to 5.8 ± 1.1 mm).

With the numbers available, no influence of the length of spur, body mass index or shoe size on the thickness of the plantar fascia could be detected, both on the symptomatic and asymptomatic side.

Discussion

Several authors discussed the appearance of plantar fasciitis as investigated with ultrasonography or MRI [2, 5, 13, 31, 34, 35]. In all of these studies, the thickness of the plantar fascia was significantly greater on the symptomatic side compared with the asymptomatic side. Taking the standard deviations into account, our results matched the results found in the literature.

To our knowledge, the ultrasonographic appearance of the plantar fascia after ESWT has not yet been described. We found a significant decrease in the thickness of symptomatic plantar fascias after ESWT. Kane et al. [13] described the same finding in symptomatic plantar fascias following a corticoid injection. The thickness of the plantar fascia seems to be related to the response to treatment.

This could be underlined by our finding regarding the pain estimation after ESWT. Pain during activities of daily living decreased by 79% on the VAS, and the comfortable walking time increased, both significantly. Moreover, those patients with little pain (VAS<30) 6 months after ESWT showed significantly thinner plantar fascias on the symptomatic side than those patients with more pain persisting.

In the literature, success rates regarding the pain estimation after ESWT in patients with plantar fasciitis varied from 70% after 5 months in the study of Hammer et al. [9] to 48% described by Rompe et al. [25] and 83% by Hammer et al. [10] after 6 months. Success rates of 58% after 12 months [15] and 77.4% after 24 months [24] have been reported. Our result of pain reduction corresponded with that in earlier studies.

However, apart from other positive results of ESWT for plantar fasciitis [1, 3, 19, 27, 32, 36], in the recent literature there are studies that quoted limited or no use of ESWT. Buchbinder et al. [4] detected no significant effect against placebo after 6 and 12 weeks. Melegati et al. [18] reported a negative effect of previous steroid injections on the result of ESWT. Helbig et al. [11] stated

that results after ESWT of patients with plantar fasciitis were better if the symptoms were more chronic. To compare all these results, a meta-analysis is necessary due to different study protocols.

With the numbers available, we could not detect any influence of different morphological factors such as the length of a heel spur, body mass index or shoe size on the thickness of the plantar fascia or the outcome after ESWT treatment.

The definite mechanism of ESWT remains unclear. The concept of shock waves in orthopaedic disorders is that they stimulate or reactivate healing processes in tendons, surrounding tissue and bone probably through microdisruption of avascular or minimally vascular tissues to encourage revascularisation, release of local growth factors, and the recruitment of appropriate stem cells conducive to more normal tissue healing [33].

In summary, we found the chronically painful, proximal plantar fascia to be ultrasonographically thicker than the pain-free control side. After ESWT, the decrease in thickness of the symptomatic plantar fascia as well as the improvement of pain and walking time were significant. Six months after ESWT, patients with little pain (VAS<30) had significantly thinner plantar fascias than patients with more pain persisting. The thickness of the plantar fascia seems to be related to the response to treatment.

References

1. Abt T, Hopfenmuller W, Mellerowicz H (2002) Shock wave therapy for recalcitrant plantar fasciitis with heel spur: a prospective randomized placebo-controlled double-blind study. *Z Orthop* 140:548–554
2. Berkowitz JF, Kier R, Rudicel S (1991) Plantar fasciitis: MR imaging. *Radiology* 179:665–667
3. Buch M, Knorr U, Fleming L, Theodore G, Amendola A, Bachmann C, Zingas C, Siebert WE (2002) Extracorporeal shockwave therapy in symptomatic heel spurs. An overview. *Orthopade* 31:637–644
4. Buchbinder R, Ptasznik R, Gordon J, Buchanan J, Prabakaran V, Forbes A (2002) Ultrasound-guided extracorporeal shock wave therapy for plantar fasciitis: a randomized controlled trial. *JAMA* 288:1364–1372
5. Cardinal E, Chhem RK, Beauregard CG, Aubin B, Pelletier M (1996) Plantar fasciitis: sonographic evaluation. *Radiology* 201:257–259
6. Davies MS, Weiss GA, Saxby TS (1999) Plantar fasciitis: how successful is surgical intervention? *Foot Ankle Int* 20:803–807
7. Furey JG (1975) Plantar fasciitis: the painful heel syndrome. *J Bone Joint Surg Am* 57:672–673
8. Gill LH (1997) Plantar fasciitis: diagnosis and conservative management. *J Am Acad Orthop Surg* 5:109–117
9. Hammer DS, Rupp S, Ensslin S, Kohn D, Seil R (2000) Extracorporeal shock wave therapy in patients with tennis elbow and painful heel. *Arch Orthop Trauma Surg* 120:304–307
10. Hammer DS, Rupp S, Kreutz A, Pape D, Kohn D, Seil R (2002) Extracorporeal shock wave therapy (ESWT) in patients with chronic proximal plantar fasciitis. *Foot Ankle Int* 23:309–313
11. Helbig K, Herbert C, Schostok T, Brown M, Thiele R (2001) Correlations between the duration of pain and the success of shock wave therapy. *Clin Orthop* 387:68–71
12. Husskisson EC (1974) Measurement of pain. *Lancet* 2:1127–1131

13. Kane D, Greaney T, Shanahan M, Duffy G, Bresnihan B, Gibney R, Fitz Gerald O (2001) The role of ultrasonography in the diagnosis and management of idiopathic plantar fasciitis. *Rheumatology* 40:1002–1008
14. Krischek O, Rompe JD, Hopf C, Vogel J, Herbsthofer B, Nafe B, Bürger R (1998) Die extrakorporale Stoßwellentherapie bei Epicondylitis humeri radialis oder ulnaris—eine prospektive, kontrollierte, vergleichende Studie. *Z Orthop* 136:3–7
15. Krischek O, Rompe JD, Herbsthofer B, Nafe B (1998) Symptomatische niedrig-energetische Stoßwellentherapie bei Fersenschmerzen und radiologisch nachweisbarem plantaren Fersensporn. *Z Orthop* 136:169–174
16. Loew M, Jurgowski W, Mau HC, Thomsen M (1995) Treatment of calcifying tendinitis of rotator cuff by extracorporeal shock waves: a preliminary report. *J Shoulder Elbow Surg* 4:101–106
17. Martin RL, Irrgang MS, Conti SF (1998) Outcome study of subjects with insertional plantar fasciitis. *Foot Ankle Int* 19:803–811
18. Melegati G, Tornese D, Bandi M, Caserta A (2002) The influence of local steroid injections, body weight and the length of symptoms in the treatment of painful subcalcaneal spurs with extracorporeal shock wave therapy. *Clin Rehabil* 16:789–794
19. Ogden JA, Alvarez R, Levitt R, Cross GL, Marlow M (2001) Shock wave therapy for chronic proximal plantar fasciitis. *Clin Orthop* 387:47–59
20. Prichasuk S, Subhadrabandhu T (1994) The relationship of pes planus and calcaneal spur to plantar heel pain. *Clin Orthop* 306:192–196
21. Richardson EG (1987) The foot in adolescents and adults. In: Crenshaw AH (ed) *Campbell's operative orthopaedics*, Vol 2. CV Mosby, St Louis, pp 933–937
22. Rompe JD, Hopf C, Küllmer K, Heine J, Bürger R, Nafe B (1996) Low-energy extracorporeal shock wave therapy for persistent tennis elbow. *Int Orthop* 20:23–27
23. Rompe JD, Hopf C, Küllmer K, Heine J, Bürger R (1996) Analgetic effect of extracorporeal shock wave therapy on chronic tennis elbow. *J Bone Joint Surg Br* 78:233–237
24. Rompe JD, Hopf C, Nafe B, Bürger R (1996) Low energy extracorporeal shock wave therapy for painful heel: a prospective controlled single-blind study. *Arch Orthop Trauma Surg* 115:75–79
25. Rompe JD, Küllmer K, Eysel P, Riehle HM, Bürger R, Nafe B (1996) Niedrigenergetische extrakorporale Stoßwellentherapie (ESWT) beim plantaren Fersensporn. *Orthop Praxis* 32:271–275
26. Rompe JD, Burger R, Hopf C, Eysel P (1998) Shoulder function after extracorporeal shock wave therapy for calcific tendinitis. *J Shoulder Elbow Surg* 7:505–509
27. Rompe JD, Schoellner C, Nafe B (2002) Evaluation of low-energy extracorporeal shock-wave application for treatment of chronic plantar fasciitis. *J Bone Joint Surg Am* 84:335–341
28. Sammarco GJ, Helfrey RB (1996) Surgical treatment of recalcitrant plantar fasciitis. *Foot Ankle Int* 17:520–526
29. Seil R, Rupp S, Hammer DS, Ensslin S, Gebhardt T, Kohn D (1999) Extrakorporale Stoßwellentherapie bei der Tendinosis calcarea der Rotatorenmanschette: Vergleich zweier Behandlungsprotokolle. *Z Orthop* 137:310–315
30. Shikoff MD, Figura MA, Postar SE (1986) A retrospective study of 195 patients with heel pain. *J Am Podiatr Med Assoc* 76:71–75
31. Steinborn M, Heuck A, Maier M, Schnarkowski P, Scheidler J, Reiser M (1999) MRI of plantar fasciitis. *Rofo Fortschr Geb Rontgenstr Neuen Bildgeb Verfahr* 170:41–46
32. Strash WW, Perez RR (2002) Extracorporeal shockwave therapy for chronic proximal plantar fasciitis. *Clin Podiatr Med Surg* 19:467–476
33. Thiel M (2001) Application of shock waves in medicine. *Clin Orthop* 387:18–21
34. Tsai WC, Chiu MF, Wang CL, Tang FT, Wong MK (2000) Ultrasound evaluation of plantar fasciitis. *Scand J Rheumatol* 29:255–259
35. Vohra PK, Kincaid BR, Japour CJ, Sobel E (2002) Ultrasonographic evaluation of plantar fascia bands. A retrospective study of 211 symptomatic feet. *J Am Podiatr Med Assoc* 92:444–449

36. Weil LS Jr, Roukis TS, Weil LS, Borrelli AH (2002) Extracorporeal shock wave therapy for the treatment of chronic plantar fasciitis: indications, protocol, intermediate results, and a comparison of results to fasciotomy. *J Foot Ankle Surg* 41:166–172
37. Wolgin M, Cook C, Graham C, Mauldin D (1994) Conservative treatment of plantar heel pain: long-term follow-up. *Foot Ankle Int* 15:97–102

Table 1. Thickness of the plantar fascia (ultrasonographic measurement) on the symptomatic and asymptomatic side before and after extracorporeal shock wave therapy (ESWT)

	f=0	f=6 weeks	f=12 weeks	f=24 weeks
	n=22	n=22	n=20	n=16
Plantar, fasciitis±SD (mm)	5.2±1.5	4.5±1.4	4.7±1.4	4.4±1.0
Pain-free, control±SD, side (mm)	4.3±1.1	4.2±1.2	4.5±1.5	4.0±0.7

Table 2. Pain on the visual analogue scale (VAS) and comfortable walking time (h) before and after ESWT

	t=0	t=6 weeks	t=12 weeks	t=24 weeks
	n=22	n=22	n=20	n=16
VAS±SD	42.5±27.3	34.6±34.7	7.5±20.0	7.5±18.8
Daily activities	78.2±18.0	30.0±35.8	25.5±31.1	16.3±30.9
Single-leg stance	79.6±17.0	34.8±36.0	28.5±36.2	16.6±30.9
Walking time±SD (h)	0.1±0.3	6.7±7.9	7.5±7.9	9.8±7.5